

## CASE REPORT

## ABDOMINAL COCOON SYNDROME: A CASE REPORT

Khizar Hayat<sup>1✉</sup>, Mariya Rizwan Butt<sup>2</sup>, Komal Khalid<sup>3</sup>, Husnain Ahmad<sup>4</sup><sup>1</sup>Pathology Department Pak Red Crescent Medical and Dental College, Dina Nath-Pakistan<sup>2</sup>Services Institute of Medical Sciences, Lahore-Pakistan<sup>3</sup>Department of Neurosurgery at Hameed Latif Hospital, Lahore-Pakistan<sup>4</sup>Ch. Pervaiz Ilahi Institute of Cardiology, Multan-Pakistan

Abdominal cocoon syndrome is an unusual cause of small bowel obstruction characterized by encasement of the bowel by a fibrous and/or collagenous membrane. A 38-year-old male, with no comorbidities, presented with signs and symptoms of sub-acute intestinal obstruction for the last one and a half months. He had two episodes of similar symptoms in the past year. It is a rare disease. Patients usually present with symptoms of recurrent obstruction of the small bowel, usually without any obvious cause. The preferred imaging modality is a CT scan however diagnosis is usually made intra-operatively. Surgical excision of membranes carries a very good prognosis. Abdominal cocoon syndrome is a rare cause of obstruction of the small bowel where preoperative diagnosis usually is difficult. Treatment of choice is meticulous surgical excision of the membranes.

**Keywords:** Abdominal cocoon syndrome; Small bowel obstruction; Collagenous membrane

**Citation:** Hayat K, Butt MR, Khalid K, Ahmad H. Abdominal cocoon syndrome: A case report. J Ayub Med Coll Abbottabad 2025;37(3):401–3.

**DOI:** 10.55519/JAMC-03-13112

## INTRODUCTION

Sclerosing Encapsulating Peritonitis, also known as Abdominal Cocoon Syndrome (ACS), is an uncommon and unusual cause of intestinal obstruction due to the encasement of the small bowel by a fibrous and/or collagenous membrane that is devoid of mesothelium. It can be divided into 2 types based on the presence of causative factors: Primary/idiopathic and secondary. The secondary form is more common occurring usually as a result of peritoneal dialysis, intestinal tuberculosis, endometriosis, peritonitis, and sarcoidosis.<sup>1</sup>

Since there is very limited literature on the topic because of very few cases reported from all over the world, and the clinical features are non-specific, abdominal cocoon syndrome is usually diagnosed intra-operatively in patients presenting with features of obstruction of the small bowel. A contrast CT scan preoperatively may show a membrane encapsulating the bowel. Definite treatment is surgical with adhesiolysis performed after the excision of the membranes.<sup>2</sup>

This report presents a case of Abdominal Cocoon Syndrome, diagnosed after recurrent complaints, abdominal CT scan, and typical intra-operative findings. The patient was subsequently surgically treated and is currently healthy.

## CASE REPORT

A 38-year-old male presented to the emergency department with a complaint of pain in his right hemi abdomen for the last one and a half months. It was gradual in onset, intermittent, severe colicky, non-

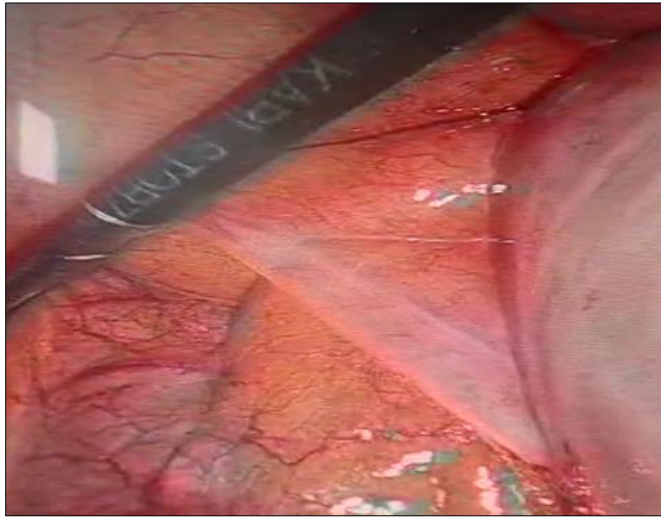
radiating, and progressively increasing in intensity. It was aggravated by movement and relieved by medications. It was associated with vomiting 2-3 episodes per day for the last 3 days which was greenish, non-projectile, occurring mostly after food intake, and preceded by nausea. There was no history of fever, constipation, per rectal bleed, or melena. The patient gave a history of similar episodes twice in the last year. Both episodes were relieved by conservative symptomatic management in 5–7 days. He had no history of any previous surgeries, any comorbid condition, or any long-term medication intake.

On examination, his abdomen was distended, more in the right hemi abdomen. All laboratory examinations were normal except for raised ALT 90 U/l (reference range 5–42 U/l) and AST 100 U/l (reference range 5–40 U/l). Stool Calprotectin done by automated ELISA was significantly elevated at 225.3 ug/g. Anti-tissue transglutaminase IgA was negative. CT Abdomen and pelvis performed after intravenous contrast confirmed the presence of a right paraduodenal internal abdominal hernia. Clustered small bowel loops including distal jejunum as well as ileum were noted within the sac of the peritoneum inferior to the third part of the duodenum. There was distension of the herniated bowel loops. There was no evidence of inflammatory bowel disease, intestinal tuberculosis, or dynamic bowel obstruction. Preoperative echocardiography however revealed an incidental finding of severe posterior mitral leaflet prolapse (Carpentier class II) leading to severe eccentric mitral regurgitation. The left ventricle was of

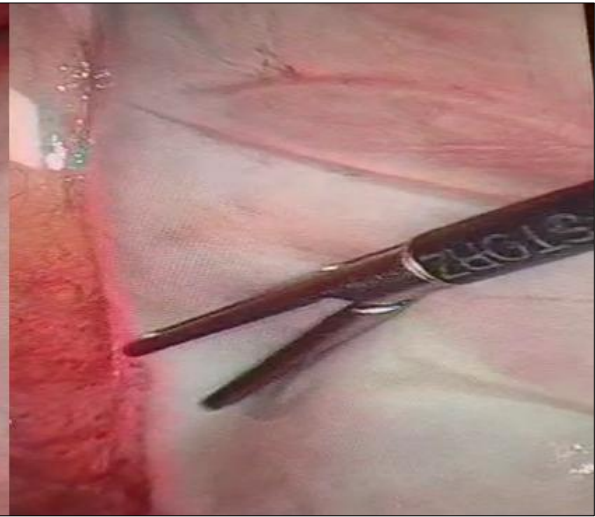
full size with good systolic function and volume overload.

Patient's clinical condition failed to improve after conservative management hence an exploratory laparoscopy followed by an exploratory laparotomy was performed. Intraoperatively, a fibrous membrane was seen encapsulating parts of jejunum and ileum.

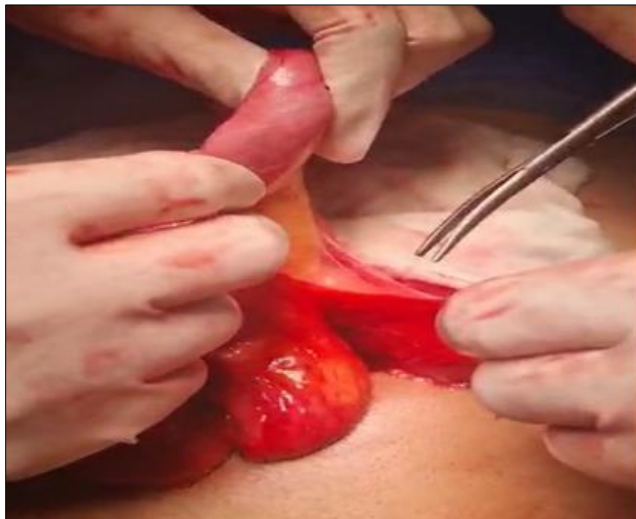The membrane was then resected and adhesiolysis was performed. All parts of the gut were viable and no injuries to the bowel were noted. A drain was inserted and abdominal incision was closed. Patient was subsequently discharged after recovery and is currently healthy.



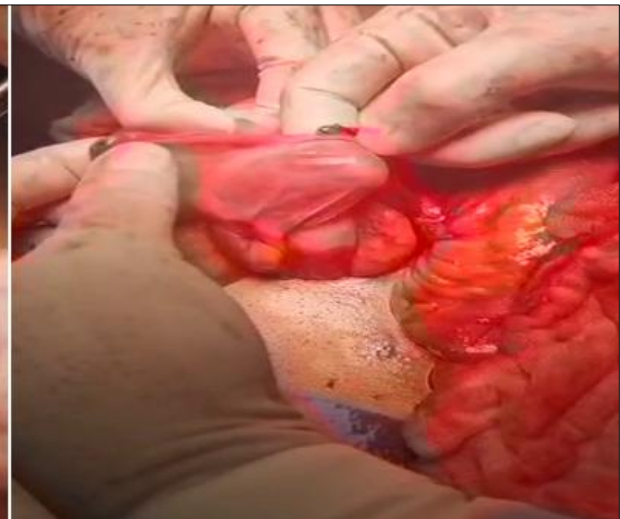
**Figure-1.1: A thin membrane encasing intestines (Laparoscopic Image)**



**Figure-1.2: Visible fibrosis (Laparoscopic Image)**



**Figure-2.1: Surgeons separating the fibrous layer (During Exploratory Laparotomy)**



**Figure-2.2: The separated fibrous layer can be seen clearly (Exploratory Laparotomy)**

## DISCUSSION

ACS is a rare disease affecting the small bowel and leading to its obstruction. The exact cause is still not known; however, it is classified into primary and secondary forms. The secondary form is more common, occurring as a consequence of peritoneal irritation by trauma or surgery, intra-peritoneal

medical therapy, intra-peritoneal chemotherapy, peritoneal dialysis, long-term beta-blocker therapy, autoimmune diseases, and infective causes.<sup>3</sup> It was thought to be more common in young girls but is now proven to be more prevalent in males. A recent review reported a total of just 193 cases all over the world, most of which were in Nigeria, India, China, and Turkey<sup>4</sup> ACS presents as obstruction of the small

bowel, either acute or sub-acute, and usually without an obvious cause, and preoperative diagnosis usually may not be possible. However, a preoperative diagnosis may prevent resection of the bowel. Differentials include other causes of acute or sub-acute small bowel obstruction as well as a developmental anomaly called Peritoneal Encapsulation, where the whole bowel is encapsulated by a thin membrane. Other differentials are Pseudomyxoma peritonei and Sclerosing malignant lymphoma and Internal Hernia.

M Anajjar *et al.* reported a case from Morocco of a 38-year-old woman who presented with intermittent and chronic abdominal pain, nausea and weight loss of 8 kg. Physical examination revealed abdominal distension with no visceromegaly. All lab investigations, except a mildly elevated C-reactive protein, were normal. Contrast enhanced CT scan of abdomen revealed ascites in perihepatic and perisplenic space and omental cake formation. Very similarly to our case, Abdominal Cocoon Syndrome was not suspected and laparoscopy was performed to rule out ascites of tumoral or tubercular origin. Fibrous membranes encapsulating the bowel were noted intraoperatively and diagnosis was made.<sup>5</sup>

Humood A. Alsadery *et al.* reported 2 cases from India, both young and male, presenting with signs and symptoms suggestive of intermittent subacute intestinal obstruction. Both were diagnosed preoperatively as Abdominal cocoon Syndrome on abdominal CT. The patients underwent surgical excision of the fibrous membranes and were discharged without any complications.<sup>6</sup> This further supports previous data about its prevalence being higher in males, the high level of suspicion needed to make a preoperative diagnosis based on radiological findings and an excellent prognosis after careful resection of membrane, as discussed in previously available studies on the topic.

CT is considered the gold standard preoperative diagnostic imaging tool. Abdominal X-rays and ultrasound may not be very useful in differentiating ACS from other diseases.<sup>7</sup> Definitive

diagnosis is most often made intra-operatively. Conservative treatment includes the use of corticosteroids and immune-suppressants. The preferred treatment however consists of careful surgical excision of the encapsulating membranes, either by laparotomy or laparoscopically. Bowel resection is performed when the gut is non-viable. The prognosis of operative management has been reported to be excellent.<sup>8</sup>

## CONCLUSION

ACS is a disease that is rare and difficult to diagnose, but surgeons should be aware of its possibility as the combination of clinical findings and imaging modalities can aid in diagnosis preoperatively and prevent the need for bowel resection. Definitive management of ACS is by careful excision of the membranes surgically.

## REFERENCES

1. Solak A, Solak I. Abdominal cocoon syndrome: Preoperative diagnostic criteria, good clinical outcome with medical treatment and review of the literature. *Turkish J Gastroenterol* 2012;23(6):776–9.
2. Mandavdhare HS. Abdominal cocoon: An enigmatic entity. *Trop Gastroenterol* 2016;37(3):156–67.
3. Solmaz A, Tokoçin M, Arıcı S, Yiğitbaş H, Yavuz E, Gülçiçek OB, *et al.* Abdominal Cocoon Syndrome is a Rare Cause of Mechanical Intestinal Obstructions: A Report of Two Cases. *Am J Case Rep* 2015;16:77–80.
4. Sovatzidis A, Nikolaidou E, Katsourakis A, Chatzis I, Noussios G. Abdominal Cocoon Syndrome: Two Cases of an Anatomical Abnormality. *Case Rep Surg* 2019;2019:32476919.
5. Anajjar M, Joumi NN, Fadili A, Akhdamch A, Nsengiyumva P, Atmani W, *et al.* Abdominal Cocoon: A Forgotten Diagnosis. *Asian J Case Rep Surg* 2023;6(2):591–7.
6. Alsadery HA, Busbait S, AlBlawi A, Alsawidan M, AlBisher HM, Alshammary S. Abdominal cocoon syndrome (idiopathic sclerosing encapsulating peritonitis): An extremely rare cause of small bowel obstruction—Two case reports and a review of literature. *Front Med (Lausanne)* 2022;9:1003775.
7. Sharma D, Nair RP, Dani T, Shetty P. Abdominal cocoon—A rare cause of intestinal obstruction. *Int J Surg Case Rep* 2013;4(11):955–7.
8. Uzunoglu Y. Rare etiology of mechanical intestinal obstruction: Abdominal cocoon syndrome. *World J Clin Cases* 2014;2(11):728.

Submitted: March 18, 2024

Revised: March 22, 2025

Accepted: March 22, 2025

### Address for Correspondence:

**Khizar Hayat**, Pathology Department Pak Red Crescent Medical and Dental College, Dina Nath-Pakistan

Cell: +92 307 425 9826

Email: hayat.khizar7475@gmail.com